

Diagnosis and Management of the Acute Red Eye

Ahmed R. Mahmood, MD, Aneesh T. Narang, MD*

*Department of Emergency Medicine, Boston Medical Center, Dowling 1 South,
1 Boston Medical Center Place, Boston, MA 02118, USA*

The red eye is a clinical problem encountered on a daily basis in most emergency departments. Fortunately, most causes are relatively benign and self-limiting; however, many conditions associated with high morbidity and that are potentially vision threatening may manifest as a red eye. The history should address the following essential components: the presence or absence of pain, foreign body sensation, and itching; the presence and type of discharge; photophobia; onset; visual disturbances; recent illnesses and trauma; and ophthalmologic history. The examination must include visual acuity, pupil shape and reactivity, a comparison between the pupils, the gross appearance of the sclera and conjunctiva, extraocular muscle function, and palpation for preauricular nodes. Often, evaluation of the affected eye requires measurement of intraocular pressure, fluorescein staining and a cobalt blue light, and a slit lamp evaluation [1].

Emergency physicians should be adept at recognizing high-risk features from the history and examination that would require urgent ophthalmologic referral and treatment. The differential diagnosis of the red eye is extensive. Some of the more common causes, including viral, allergic, and bacterial conjunctivitis, subconjunctival hemorrhage, episcleritis, scleritis, anterior uveitis, and acute angle-closure glaucoma (AACG), are discussed herein. Characteristic features of the history and examination as well as management and indications for ophthalmology consultation for each of these entities are described in detail.

Conjunctivitis

The most common cause of red eye is conjunctivitis. The term *conjunctivitis* refers to inflammation of the conjunctiva, a membrane that lines the

* Corresponding author.

E-mail address: atnarang@yahoo.com (A.T. Narang).

outer aspect of the globe (bulbar conjunctiva) and reflects back on itself to line the inner lids (the palpebral conjunctiva) [2]. Conjunctivitis is usually separated into broad categories based on the etiologic agent and time course of illness. The most common causes of acute conjunctivitis (less than 4 weeks) are allergic, viral, and bacterial. Common and distinguishing features of the various types of acute conjunctivitis are reviewed herein.

Allergic conjunctivitis, also known as hay fever conjunctivitis or seasonal allergic rhinoconjunctivitis, is the most common type of ocular allergy. This IgE-mediated reaction is usually, but not always, seasonal and may be seen with sensitivity to allergens such as dust or animal dander. The patient will almost always present with itching and may or may not have associated watery eyes and rhinorrhea. If there is no component of itching, allergic conjunctivitis is less likely, and another diagnosis should be sought. The family history often includes other forms of atopy such as asthma, eczema, or allergic rhinitis. On examination, the clinician will notice a global bilateral injection pattern that is equal in both eyes [1]. If there is a discharge, it may be clear and watery, such as in tears, or mucoid. Mild eyelid swelling may complete the clinical presentation. Similar presentations can be caused by dry eyes, contact lenses, and over-the-counter eye products, and these causes should be considered in the differential diagnosis [2].

As with the treatment of other forms of allergy, avoidance of triggers is paramount. The patient may use cold compresses, over-the-counter vasoconstrictors, or ocular non-steroidal anti-inflammatory agents (NSAIDs) to help reduce discomfort, redness, and swelling. Oral antihistamines can often help relieve many of the patient's symptoms. More specific therapy includes histamine-blocking drops such as olopatadine, pemirolast, or ketotifen [1]. Topical mast cell stabilizers such as cromolyn sodium or lodoxamide can also be beneficial. Administering corticosteroids should only be done in consultation with an ophthalmologist [2].

Conjunctivitis can have a variety of infectious etiologies. Viral infections are among the most common forms of infectious conjunctivitis, with many types implicated, including adenovirus, herpes, mumps, and rubella. Because the last two causes are rare, the more common presentations of adenovirus and herpes virus are discussed herein. Adenovirus is the most likely etiologic agent of any viral conjunctivitis, with most of the common serotypes causing a mild follicular conjunctivitis. Common modes of transmission for this viral-borne illness are the fingers, medical instruments, and swimming pool water. As such, it is responsible for community-wide epidemics and is commonly found in schools, workplaces, and doctors' offices [2]. The patient will usually complain of irritation beginning in one eye and spreading to the other a few days later. This spread is not uncommon as the infection is transmitted via hand-eye contact. Some patients may have an associated upper respiratory tract infection. Common but nonspecific findings include preauricular lymphadenopathy, global conjunctival injection, watery discharge, and a follicular reaction of the inferior tarsal conjunctiva

(Fig. 1). Follicles are tiny, avascular, round, white or gray patches on the palpebral conjunctiva. They differ from papules, which are larger, include a tuft of blood vessels, and resemble cobblestones [3]. Pain and photophobia are not typically associated with most instances of adenoviral conjunctivitis. Likewise, blurred vision that does not clear on blinking may be an indication that another diagnosis should be considered [2].

Treatment for most cases of viral conjunctivitis includes supportive care such as artificial tears and cold compresses. Topical decongestants and topical steroids (in consultation with an ophthalmologist) may be prescribed if the ocular edema is severe. Because viral conjunctivitis is usually a benign and self-limiting condition, there is a low likelihood of secondary bacterial infection. Topical antibiotics such as erythromycin are not necessary; however, it is not inappropriate to prescribe antibiotics if the diagnosis is difficult to discern from bacterial conjunctivitis. Fortunately, there is little harm in using topical antibiotics for viral conjunctivitis [4]. Adenovirus has been found to have a 95% replication rate at 10 days, which drops to 5% at 16 days. The patient should be instructed to practice frequent hand washing for 2 weeks and should be reminded that personal items that may come in contact with the eyes, such as towels, should not be shared [1]. In most cases, viral conjunctivitis can be managed on an outpatient basis with elective referral to an ophthalmologist if there is no improvement within 7 to 10 days [5].

Depending on the serotype of adenovirus, the clinical presentation may include more than just a mild follicular conjunctivitis. Of the 47 adenoviral serotypes, many have a predilection for other mucosal surfaces in addition to the bulbar and palpebral conjunctiva. These serotypes can cause a clinically significant infection in the respiratory, genitourinary, or gastrointestinal tracts as well; hence, adenoviral conjunctivitis may be isolated or a feature of a systemic viral syndrome. Two of the more common syndromes

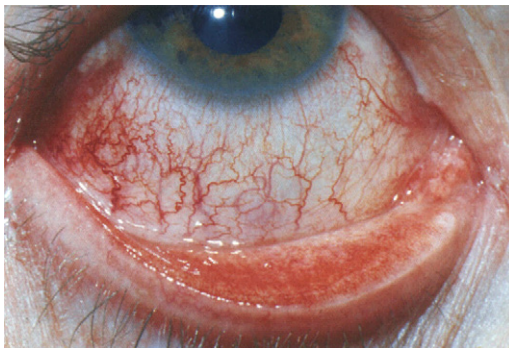

Fig. 1. Viral conjunctivitis. Note the global injection pattern. (From Boruchoff SA. Anterior segment disease: a diagnostic color atlas. Boston: Butterworth-Heinemann; 2001. p. 120; with permission.)

are pharyngoconjunctival fever and epidemic keratoconjunctivitis. Pharyngoconjunctival fever presents with an abrupt onset of high fever, pharyngitis, and bilateral follicular conjunctivitis. It is more common in children and can occur sporadically and in clusters. Schools during the winter and camps during the summer are common settings for this type of infection. Treatment is the same as for mild follicular conjunctivitis, with referral to ophthalmology if symptoms are unremitting after 1 week. Epidemic keratoconjunctivitis is frequently caused by serotypes 8, 19, and 37 and is associated with ocular pain and decreased visual acuity from corneal subepithelial infiltrates (Fig. 2). The infiltrates appear as 1- to 2-mm, grayish-white, “crumb-like” defects numbering up to 30 throughout the central and peripheral cornea. Visual acuity may drop by several lines on the Snellen chart. Edema, small petechial hemorrhages, and the formation of inflammatory pseudomembranes are other distinctive features of epidemic keratoconjunctivitis [3]. Treatment should consist of local care as outlined previously. Patients should receive follow-up with an ophthalmologist in 1 week to monitor for the development of keratitis, a complication of keratoconjunctivitis [6].

Herpes simplex virus (HSV) conjunctivitis is an example of another infection that may present as a conjunctivitis alone or as a more pervasive infection involving the cornea, eyelid, and skin. HSV conjunctivitis occurs at a higher rate in HIV-infected patients. This infection will usually present unilaterally and has many of the features of an adenovirus conjunctivitis, including a watery discharge and palpable preauricular nodes. Pain, burning, and a foreign body sensation associated with HSV conjunctivitis help distinguish it from most other forms of viral conjunctivitis. Other distinguishing features include episodic copious tearing and mildly decreased vision [3]. The first-line treatment for patients who have HSV conjunctivitis alone, without skin or corneal involvement, is cool compresses and topical antiviral medication for 10 to 14 days. Recommended medications are trifluridine 1% drops, five times per day, or vidarabine 3% ointment, five times

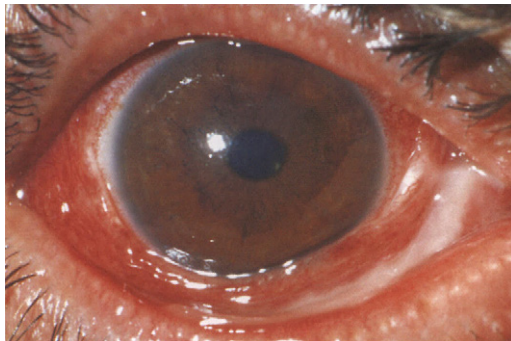


Fig. 2. Epidemic keratoconjunctivitis. (From Boruchoff SA. Anterior segment disease: a diagnostic color atlas. Boston: Butterworth-Heinemann; 2001. p. 132; with permission.)

per day. The patient should receive follow-up in 2 to 5 days to monitor for corneal involvement [7].

If HSV conjunctivitis also involves the skin (eg, HSV dermatitis of the eyelids) or is associated with photophobia or decreased vision, the clinician must be more aggressive with work-up and treatment. In these circumstances, corneal staining should be performed. On slit lamp examination, one may see pinpoint or dendritic lesions on the cornea using fluorescein staining and a cobalt blue light. The lesions may be confluent and geographic, or atypical. Classic skin findings include grouped pustules or vesicles on an erythematous base which progress to crusting. The patient may have a history of similar bouts of conjunctivitis, usually unilateral, suggesting remote HSV outbreaks. Stress, fever, trauma, or UV light can all trigger reactivation. In severe cases, uveitis, iritis, and increased intraocular pressure may be seen. Treatment consists of topical trifluridine 1% drops administered nine times per day and oral acyclovir, 400 mg orally five times daily for 7 to 10 days. If there is flare in the anterior chamber on slit lamp examination, one should consider the addition of a cycloplegic agent such as scopolamine 0.25% three times daily. The patient should undergo an ophthalmologic follow-up in 2 days to evaluate for response to treatment [7]. Steroids should not be prescribed for patients with HSV conjunctivitis because the risk for secondary infection and other complications from uncontrolled viral proliferation is increased [2].

Herpes zoster (HZV) ophthalmicus occurs when the varicella-zoster virus is reactivated in the ophthalmic division of the trigeminal nerve. This entity represents approximately 10% to 25% of all zoster cases. Although most cases of HZV ophthalmicus involve the skin only, serious ocular involvement can occur if the infection is reactivated in the nasociliary branch of the ophthalmic nerve (Fig. 3A, C). Herpes pustules at the tip of the nose (Hutchinson's sign) are thought to be a classic predictor of ocular involvement. Although patients with a positive Hutchinson's sign have twice the incidence of ocular involvement, one third of patients without the sign can experience ocular manifestations. A common complication of HZV infection is an injected and edematous conjunctiva, often with petechial hemorrhages. This conjunctivitis will usually resolve in 1 week unless secondary bacterial infection occurs. The use of topical antibiotics may help to prevent secondary infection, whereas cool compresses and lubrication drops can be used for comfort. In corneal involvement, HZV dendrites appear as a branching or "medusa-like" pattern with tapered ends in contrast to HSV dendrites, which often have terminal bulbs. This pattern can be viewed by Wood's lamp or slit lamp examination after fluorescein staining. These patients need preservative-free artificial tears every 1 to 2 hours and an ocular lubricant ointment nightly. An ophthalmologist should be consulted regarding systemic or topical antiviral agents; topical steroids are occasionally indicated depending on the ocular manifestations of HZV and should be prescribed only in consultation with ophthalmology [8].

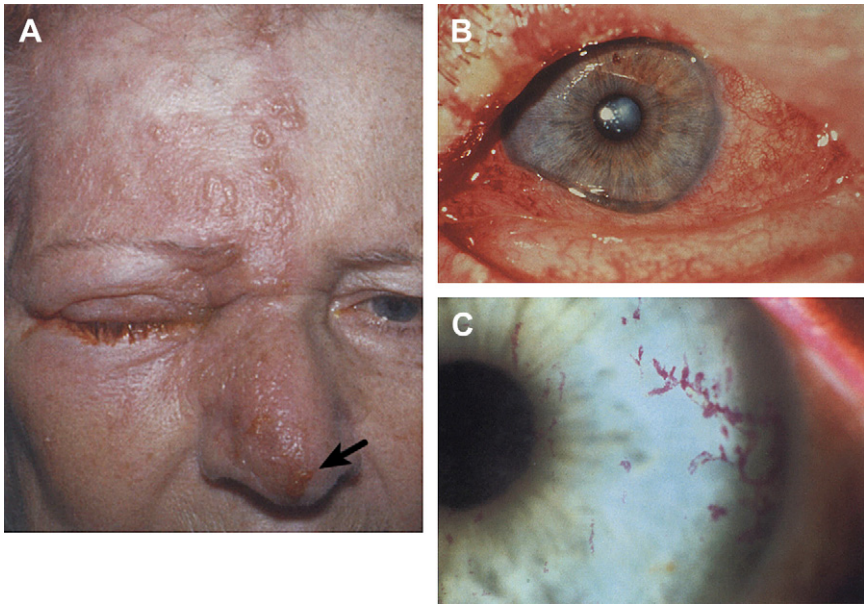


Fig. 3. (A) Herpes zoster in the distribution of the first division of the trigeminal nerve. Note the presence of Hutchinson's sign, a vesicle on the tip of the nose (black arrow). (B) Herpes zoster keratoconjunctivitis. (C) HZV dendrites have a "medusa-like" pattern. (From Boruchoff SA. Anterior segment disease: a diagnostic color atlas. Boston: Butterworth-Heinemann; 2001. p. 128–9; with permission.)

If the patient with HZV activation should have any ocular involvement, ophthalmologic follow-up should occur within 24 hours [8].

Bacterial conjunctivitis is a condition usually caused by gram-positive organisms, the most common being *Streptococcus pneumoniae* and *Staphylococcus aureus*, and gram-negative organisms such as *Haemophilus influenzae* [1]. The first two infections occur more often in children; the last afflicts mostly adults [2]. Bacterial conjunctivitis has a more abrupt onset than viral conjunctivitis and is also associated with tearing and ocular irritation. In bacterial conjunctivitis, the infection usually spreads to the contralateral eye within 48 hours [1]. The patient may complain of morning crusting and difficulty opening the eyelids [2]. This symptom results from a mucopurulent yellow-colored discharge that causes matting of the lids and lashes (Fig. 4). On examination, the red eye injection pattern of bacterial conjunctivitis is diffuse but often more pronounced at the fornices [1].

The definitive treatment for bacterial conjunctivitis is topical ophthalmic broad-spectrum antibiotics. Although it is usually a self-limiting disease, treatment shortens the course, reduces person-to-person spread, and lowers the risk of sight-threatening complications such as ulceration. Erythromycin and bacitracin/polymyxin B provide excellent broad-spectrum coverage against most pathogens found in adult and pediatric cases. Aminoglycosides

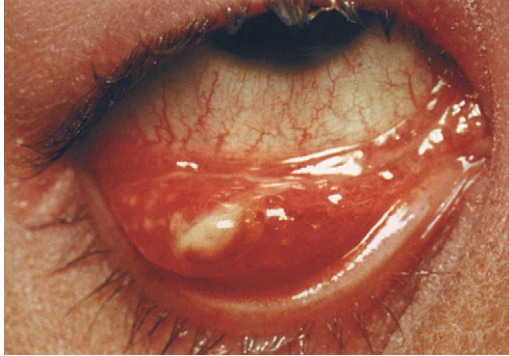

Fig. 4. Bacterial conjunctivitis. Note matting of the eyelashes caused by the mucoid and thick discharge. (From Boruchoff SA. Anterior segment disease: a diagnostic color atlas. Boston: Butterworth-Heinemann; 2001. p. 135; with permission.)

should not be used because they have relatively poor coverage of gram-positive organisms such as staphylococcus and streptococcus species. Ointment, which is less irritating, works best for children who also benefit from less frequent application and can tolerate the associated blurred vision well. Drops are recommended for adolescents and adults because they are easier to apply [2]. Most immunocompetent patients with uncomplicated cases of bacterial conjunctivitis should be seen in 3 to 4 days if there is no improvement in symptoms [9]. Bacterial conjunctivitis in young children or the debilitated should be managed conservatively and may need closer follow-up. It is wise to obtain cultures in these populations [2].

The contact lens user who has pain or redness should remove the lens immediately. After a work-up, if one suspects an infectious complication of contact lens use, the patient should discontinue lens wear. Smears and cultures, which are usually performed with ophthalmology consultation, should be obtained in patients who have an infectious corneal ulcer greater than 1 mm or when an unusual organism is suspected. Intensive antibiotic therapy should be initiated using topical fluoroquinolone, six to eight times per day, and a cycloplegic agent. The patient requires follow-up in 1 day [7].

Hyperacute conjunctivitis is a conjunctivitis caused by *Neisseria gonorrhoeae* and occurs most commonly in sexually active persons. Infection with *N meningitidis* is also known to cause hyperacute conjunctivitis but occurs less frequently and can only be differentiated from infection with *N gonorrhoeae* through laboratory testing. *N gonorrhoeae* is usually spread from genital-hand-eye contact in the young sexually active population, but neonates can acquire it from the birth canal. The infection will manifest in neonates 3 to 5 days postpartum with bilateral discharge [2].

Ocular *N gonorrhoeae* infection is abrupt in onset and produces copious amounts of purulent discharge that reforms quickly after wiping away. Marked conjunctival injection, conjunctival chemosis, lid swelling, globe

tenderness through closed lids, and preauricular lymphadenopathy may all be found on physical examination (Fig. 5). Work-up should include immediate staining for gram-negative diplococci and special cultures for *Neisseria* sp. The infection may or may not be associated with a urethral discharge. In infants born to infected mothers, the infection may be localized to other organs (arthritis, meningitis, pneumonia) or may be disseminated (sepsis) [2].

Treatment for hyperacute conjunctivitis need not be complicated. The eye should be irrigated with saline solution. Selection of topical antibiotics is the same as for bacterial conjunctivitis. It is recommended that systemic antibiotics directed against *N gonorrhoeae* be initiated, because a large number of patients with *N gonorrhoeae* conjunctivitis also have concurrent venereal disease. Urgent referral is critical in *N gonorrhoeae* infection. In contrast to bacterial conjunctivitis, hyperacute conjunctivitis can have sight-threatening outcomes secondary to ulceration and perforation [2].

Ocular chlamydial infection leads to two forms of conjunctivitis depending on the serotype of the organism. Serotypes A through C cause trachoma, a chronic keratoconjunctivitis that is the most common form of preventable blindness in the world. Inclusion conjunctivitis is caused by serotypes D through K. Inclusion conjunctivitis is a common, primarily sexually transmitted disease that affects both newborns and adults. The incidence of inclusion conjunctivitis is higher than that of ocular *N gonorrhoeae* infection in newborns. Newborns acquire the infection in the birth canal and cervix and present with tearing, conjunctival inflammation, and eyelid swelling with moderate discharge starting from 5 to 12 days after birth. In adults, inclusion conjunctivitis is transmitted via genital secretions and may be a result of autoinoculation. The infection can be subacute or even chronic and is most common in young, sexually active persons aged 18 to 30 years. The adult patient will present with unilateral or bilateral redness, foreign body sensation, mucopurulent discharge, and preauricular adenopathy. Because as many as one half of affected adults will also have concurrent,

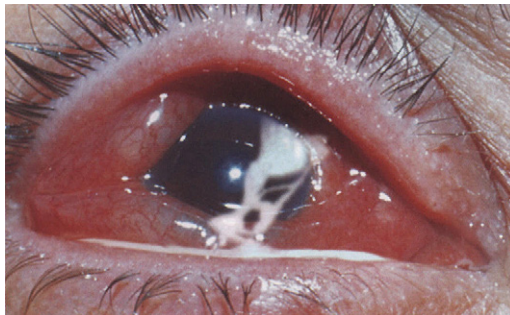


Fig. 5. Hyperacute conjunctivitis caused by *Neisseria* sp. Note the copious amounts of purulent discharge. (From Boruchoff SA. Anterior segment disease: a diagnostic color atlas. Boston: Butterworth-Heinemann; 2001. p. 136; with permission.)

possibly asymptomatic, cervical/urethral chlamydial infection, laboratory studies should be performed when inclusion conjunctivitis is suspected. A work-up for other sexually transmitted diseases such as syphilis and gonorrhea should also be considered because co-infection rates can be high [2].

In the adult, one should treat the sexual disease by prescribing azithromycin, 1 g orally for one dose, doxycycline, 100 mg orally twice daily, or erythromycin, 500 mg orally four times daily for 7 days for the patient and sexual partners. Topical erythromycin, tetracycline, or sulfacetamide ointment twice to three times daily for 2 to 3 weeks will help treat the ocular infection. Follow-up should be arranged with ophthalmology in 1 week [7]. In neonatal inclusion conjunctivitis, systemic antibiotics are commonly used in addition to topical antibiotics because this condition can be associated with otitis media and respiratory and gastrointestinal tract infections. Consultation with ophthalmology is essential because special cultures and stains may be required to direct treatment [2]. If no information regarding a specific organism is available during the initial visit, empiric therapy with erythromycin ointment four times daily and with erythromycin elixir, 50 mg/kg/d divided four times per day, may be initiated [7].

Chronic forms of conjunctivitis have many causes, such as contact lens use, prescription and over-the-counter eye drops, chlamydia, or molluscum contagiosum, as well as other less common causes. A history of collagen vascular disease or diuretic or antidepressant use raises the possibility of dry eyes as a cause of chronic conjunctivitis. Chronic unilateral conjunctivitis is a separate entity and has more causes. It presents a diagnostic dilemma even to the specialist. Possible diagnoses may include keratitis, nasolacrimal duct obstruction, occult foreign body, or ocular neoplasm. Referral is indicated in the case of chronic unilateral conjunctivitis [2].

Subconjunctival hemorrhage

Subconjunctival hemorrhage is caused by bleeding of the conjunctival or episcleral vessels deep to the conjunctiva into the subconjunctival space [10]. Subconjunctival hemorrhage can be spontaneous or related to trauma or systemic illness. When it is spontaneous, it is usually secondary to decreased lubrication of the eye [11].

The patient will usually present with a painless red eye that has no effect on his or her vision. It often causes alarm when the patient first notices it. There is no discharge associated with subconjunctival hemorrhage. The patient may recall a history of mild trauma orValsalva (such as coughing or vomiting). A history of anticoagulation therapy may also be elicited. The patient should be asked about a history of hypertension, diabetes, or any bleeding disorder because subconjunctival hemorrhage may be a presenting sign of any of these conditions [5].

On examination, subconjunctival hemorrhage appears as fresh red blood on a white sclera with clear borders and masks the conjunctival vessels

(Fig. 6). When evaluating a subconjunctival hemorrhage, one should consider staining the eye to rule out corneal injury if the history suggests it or if the patient has any type of pain associated with the subconjunctival hemorrhage [1]. If the subconjunctival hemorrhage is large and the injury occurred in the setting of trauma, there may be penetrating injury to the globe (globe rupture) that is obscured by the hemorrhage, requiring emergency ophthalmology consultation [7]. For minor subconjunctival hemorrhages, patient education and reassurance are the mainstays of treatment, and these patients do not need ophthalmology referral. Prescribing warm compresses and lubrication drops may help reduce recovery by 1 to 3 days. A high-profile subconjunctival hemorrhage will take approximately 10 to 14 days to resolve [1].

Episcleritis

The episclera is a thin membrane that covers the sclera and lies beneath the conjunctiva. Episcleritis is generally a benign inflammatory condition that involves only the superficial episcleral tissue and not the deep episcleral tissue that overlies the sclera. Most cases are idiopathic in nature and are commonly seen in young adults [12,13]. Episcleritis can be associated with systemic diseases such as rheumatoid arthritis, polyarteritis nodosa, systemic lupus erythematosus (SLE), inflammatory bowel disease, sarcoidosis, Wegener's granulomatosis, gout, HZV, or syphilis [13].

Episcleritis is usually characterized by a rapid onset of redness that may be associated with a feeling of grittiness and a dull headache. Vision is unaffected, and discharge, if present, is usually watery. On examination,

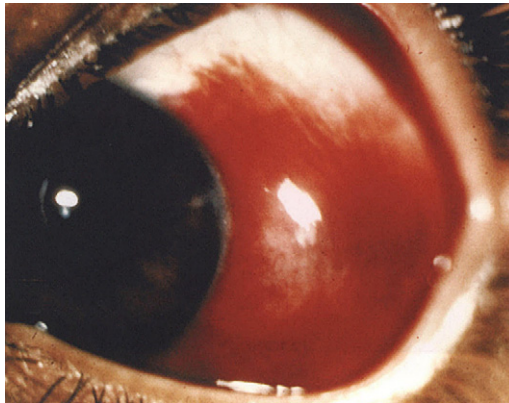


Fig. 6. Subconjunctival hemorrhage. The extravasated blood has completely obscured the sclera underneath. Note the slightly raised appearance of the affected area. (From Boruchoff SA. Anterior segment disease: a diagnostic color atlas. Boston: Butterworth-Heinemann; 2001. p. 147; with permission.)

focal areas of redness are usually observed rather than a diffuse process. White sclera may be seen between radially coursing dilated episcleral vessels [5]. The conjunctival and superficial episcleral vessels can be seen displaced outward from the sclera while the underlying deep episcleral plexus is not involved and lies flat against normal scleral tissue. This appearance is best observed using red-free light on slit lamp examination. Nodular episcleritis occurs with the presence of a tender scleral nodule and generally is more uncomfortable than simple episcleritis with a more prolonged course (Fig. 7). The engorgement of the superficial episcleral plexus gives the eye a distinct red or salmon hue, and there may be tenderness on palpation [12].

This condition is usually self-limiting and will resolve within 2 to 3 weeks even without intervention. Treatment may involve oral NSAIDs and should be referred electively to an ophthalmologist for outpatient evaluation. Topical anti-inflammatory agents and lubricants may also be helpful, but steroids should only be prescribed after consultation with an ophthalmologist [5,13].

Scleritis

Scleritis is defined as an inflammation of the sclera that may involve the cornea, adjacent episclera, and underlying uvea. The maximal involvement in scleritis is the deep episcleral plexus, which is displaced outward by the edematous swollen sclera. The classification of scleritis can be divided into anterior and posterior. Anterior scleritis is further subdivided into diffuse, nodular, or necrotizing. Diffuse anterior scleritis is characterized by extensive scleral edema and congestion of the scleral vessels with poorly defined margins. Nodular anterior scleritis is characterized by focal, often multiple well-defined nodules of scleral edema and congestion of scleral vessels distinct from its overlying inflamed episclera. Necrotizing anterior scleritis is

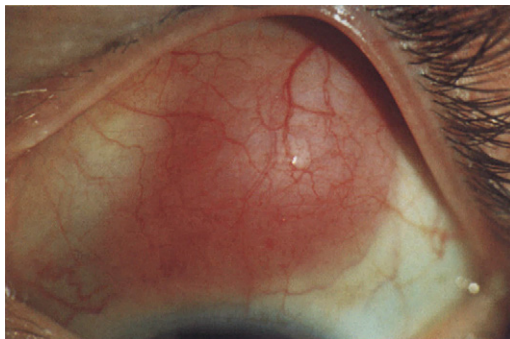


Fig. 7. Nodular episcleritis. Note the focal area of redness and dilated blood vessels. (From Boruchoff SA. Anterior segment disease: a diagnostic color atlas. Boston: Butterworth-Heinemann; 2001. p. 183; with permission.)

characterized by an avascular area of scleral necrosis and often by significant inflammation of the surrounding sclera. The sclera surrounding the necrosis may also be devoid of any prominent inflammation, which is seen in scleromalacia perforans, often associated with rheumatoid arthritis. Posterior scleritis is characterized by involvement of the sclera posterior to the insertion of the rectus muscles and may occur in association with anterior scleritis or in isolation [12].

Although most cases of scleritis are immune mediated, the disease can also be triggered by infection, surgery, malignancy, or drugs. Approximately 39% to 50% of the cases are associated with a systemic disorder. The resulting scleral inflammation may be in part or completely secondary to the immune-mediated response. A large number of connective tissue disorders are associated with scleral disease; the most common is rheumatoid arthritis. Wegener's granulomatosis is the most common vasculitis associated with this condition. Other causes include relapsing polychondritis, SLE, polyarteritis nodosa, Reiter's syndrome, inflammatory bowel disease, and progressive systemic sclerosis. Approximately 5% to 10% of anterior scleritis is infectious owing to viral, bacterial, fungal, or parasitic agents. Infectious scleritis is more likely in the presence of infectious keratitis. Infectious scleritis should be suspected in patients with a history of accidental trauma, ocular surgical procedures, or recurrent attacks of HSV or varicella-zoster virus. Herpes zoster ophthalmicus was found in one review to be the most common infectious cause of scleritis. Other common causes are syphilis, miliary tuberculosis, HSV, *Pseudomonas aeruginosa*, Epstein-Barr virus, and Coxsackie B5. A history of surgery has been shown to be a risk factor for bacterial causes of scleritis. For instance, a patient with pterygium removal may present months to years after surgery with bacterial scleritis, most often owing to *Pseudomonas aeruginosa*. When a bacterial scleritis leads to a pyogenic infection, it can be a therapeutic challenge due to the avascularity of the sclera. Fungal infections may remain undiagnosed for a long time before the exact cause is found [12].

Patients who present with scleritis either already have a known underlying systemic disorder such as rheumatoid arthritis or present de novo. Scleritis may also be the sole initial presenting feature of a systemic disease, most commonly rheumatoid arthritis [14]. Scleritis usually occurs in white, middle-aged women with a mean age of onset of 49 years, and female patients account for 71% of all cases. The characteristic feature of scleritis is severe pain that may involve the eye and orbit and radiate to the ear, scalp, face, and jaw. It is usually dull, boring, and can be so severe that it often awakes the patient from sleep or causes significant impairment in their daily activities. It may often be confused with other causes of headache, such as giant cell arteritis, migraines, cerebral aneurysm, tic douloureux, and tumor [12]. It can also be associated with photophobia, tearing, and with pain on accommodation [14]. Mild analgesics will often not relieve the pain, although some patients may present with little or no discomfort due to

the use of NSAIDs before presentation. Patients who have posterior scleritis may present with reduced vision with or without pain [12].

Many features on the physical examination will aid in making the diagnosis. The redness may be focal or diffuse, unilateral or bilateral, and present with tenderness to palpation of the globe. Nodular anterior scleritis is characterized by a localized area of scleral edema in which distinct nodules reside. Nodules may be single or multiple and are tender to palpation. In scleritis, the vascular engorgement of the deep episcleral plexus gives the eye a characteristic bluish-violet discoloration, and the deep scleral vessels will not blanch in response to vasoconstrictor agents such as 2.5% to 10% phenylephrine or 1:1000 epinephrine (Fig. 8). This characteristic is in contrast to the blanching seen with conjunctival and superficial vessels in conjunctivitis and episcleritis [12]. The hallmark of scleritis is the presence of scleral edema and congestion of the scleral plexus, which may involve the superficial and deep vascular coats. In scleritis, the vascular architecture of the superficial episcleral plexus is disrupted by the presence of irregularly oriented vessels. In episcleritis, only the superficial episcleral plexus is congested, and its radial configuration is preserved. Avascular areas strongly imply the diagnosis of necrotizing scleritis. Slit lamp examination using red-free light is helpful in characterizing the pattern and depth of episcleral vascular engorgement. The sclera will often be edematous and may cause the slit lamp light beam to be displaced forward in the area of maximal swelling. Anterior uveitis, peripheral choroiditis with or without retinal detachment, uveal effusion, or disk edema can all be seen with posterior extension of scleritis and are not seen with episcleritis [14]. In isolated posterior scleritis, the eye may be white, but sometimes inflamed posterior sclera can be visualized in the extremes of gaze. Because there may be a paucity of physical examination findings, imaging is often necessary to make the diagnosis. Posterior scleritis can be delineated using B-scan ultrasonography and high-definition orbital MRI [12].

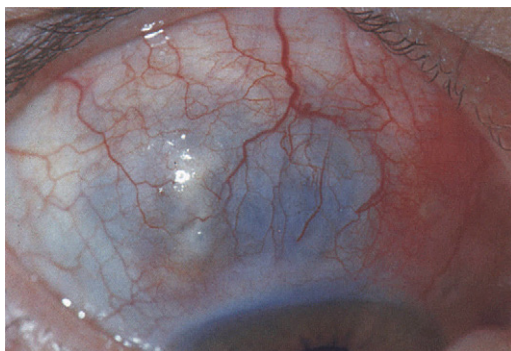


Fig. 8. Dilatation of the deep episcleral vessels and a bluish discoloration of the eye in a patient with scleritis. (From Boruchoff SA. Anterior segment disease: a diagnostic color atlas. Boston: Butterworth-Heinemann; 2001. p. 183; with permission.)

In acute presentations of scleritis, blood work may include a complete blood count, electrolytes, tests of renal function, assays for acute phase reactants such as C-reactive protein, and evaluation of the erythrocyte sedimentation rate, and serologic testing to rule out and determine the degree of associated systemic conditions may be performed [12,14]. In cases of suspected infectious scleritis, serologies and conjunctival scrapings for smears and cultures are often obtained. If these tests are negative after 48 hours and the scleritis continues to progress, scleral or corneoscleral biopsy is essential. Tests may include rapid plasma reagin and microhemagglutination-*Treponema pallidum* in cases of suspected syphilis. A positive c-ANCA in a patient with scleritis is specific for Wegener's granulomatosis. Assays for rheumatoid factor for rheumatoid arthritis and for anti-nuclear antibody suggestive of SLE, rheumatoid arthritis, polymyositis, progressive systemic sclerosis, or mixed connective tissue diseases should also be performed. Ultrasonography, an orbital CT scan, fluorescein angiography, and high-definition orbital MRI may be required to confirm the diagnosis and to assess the extent of disease [14]. Although these tests are generally not done in the emergency room setting, the consulting ophthalmologist and primary care physician should be involved in expediting the work-up and delineating the etiology.

Making this diagnosis early is important owing to associated serious complications. In a study of 358 patients with scleritis, decreased vision occurred in 37%, anterior uveitis was present in 42%, peripheral ulcerative keratitis in 14%, glaucoma in 13%, and cataracts in 17%. Elevated intraocular pressure can develop in any patient with any type of scleritis, with the rate of glaucoma ranging from 9% to 22% in anterior scleritis. Greater visual loss is generally seen in patients with systemic disease, especially in rheumatoid arthritis, and is found to be independent of corneal complications and cataracts. Necrotizing scleritis also results in greater visual loss than in the non-necrotizing form [14].

The goal of treatment is to remove or treat the underlying cause but, most importantly, to control the inflammatory process and therefore reduce damage to the eye. Patients with posterior or necrotizing scleritis need more intensive and urgent therapy than patients with anterior non-necrotizing disease. Any scleritis associated with an underlying systemic disease usually requires more aggressive immunosuppressive therapy. Approximately one third of patients with anterior scleritis will respond to NSAIDs, one third to systemic corticosteroids, and the other third to more aggressive systemic immunosuppression [14]. The diagnosis of scleritis calls for a prompt referral to an ophthalmologist and initiation of an oral NSAID initially. Further management including topical or oral corticosteroids, other immunosuppressive agents, and possible surgical intervention should be done in conjunction with the primary care physician and ophthalmologist [12]. When timely outpatient evaluation is not possible or treatment is more urgent, admission may be required.

Uveitis

Uveitis can be defined as an inflammation of the iris (iritis), ciliary body (cyclitis), and choroid (choroiditis). Anterior uveitis, often called iridocyclitis, involves inflammation of the anterior portion of the uveal tract and usually affects young or middle-aged persons. Posterior uveitis includes vitritis, choroiditis, retinitis, chorioretinitis, or retinochoroiditis. Panuveitis or diffuse uveitis are the terms used to characterize both anterior and posterior involvement. There are multiple causes of uveitis, but uveitis can generally be characterized as inflammatory, traumatic, or infectious. Uveitis has been shown to be associated with the histocompatibility antigen HLA B-27. In the United States and England, 30% to 70% of patients with anterior uveitis have this antigen. About half of these patients have an associated systemic disease such as ankylosing spondylitis, psoriatic arthritis, reactive arthritis, or inflammatory bowel disease. Many other systemic diseases may present with uveitis, including sarcoidosis, juvenile idiopathic arthritis, Behçet disease, Kawasaki disease, multiple sclerosis, and Wegener's granulomatosis [15].

Although infection is an uncommon cause of uveitis, it is important to rule it out before instituting immunosuppressive therapy. Parasitic (eg, toxoplasmosis), viral (cytomegalovirus, herpes viruses), bacterial (tuberculosis, Lyme disease), and treponemal (syphilis) agents could be responsible. Toxoplasmosis is a common cause of retinochoroiditis in normal and immunosuppressed patients and is responsible for as many as 25% of occurrences of posterior uveitis in the United States. Cytomegalovirus can cause posterior uveitis in immunocompromised individuals, particular in AIDS patients, but its incidence has decreased in the United States since antiretroviral therapy has become available. Tuberculosis was once the most common cause of choroiditis but is now found in less than 1% of all cases in the United States. Syphilis can cause both anterior and posterior uveitis, usually during the secondary or tertiary stages of infection. Traumatic iritis is commonly seen in the emergency department and is usually secondary to a direct blow from a blunt object [15].

Anterior uveitis often presents suddenly with a red and painful eye. Photophobia and conjunctival injection are often seen; sometimes blurred vision is present [1]. Patients generally complain of a deep aching pain that may radiate to the periorbital or temple area. It is worse with eye movement and during accommodation. On examination, hyperemia is prominent adjacent to the limbus (perilimbal or circumcorneal injection), in contrast to that seen in conjunctivitis in which inflammation tends to be more prominent at a distance from the limbus (Fig. 9). Tearing may be present, but no purulent discharge is seen [16]. Generally, the pupil is constricted, may be irregular, and is sluggish in response to light in comparison with the uninvolved eye. On pupillary examination, the patient may have direct photophobia when light is directed into the affected eye, as well as consensual photophobia when light is shone on the unaffected eye. Consensual

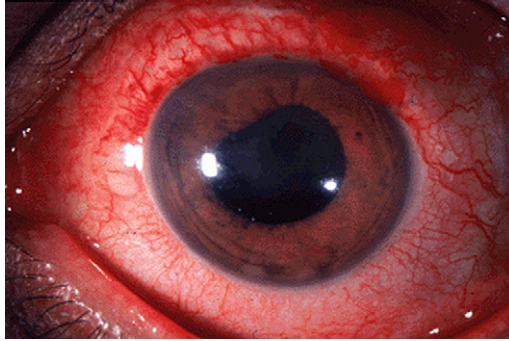


Fig. 9. Anterior uveitis. Note the perlimbal injection and the irregularly shaped pupil. (Courtesy of the University of Michigan Kellogg Eye Center, Ann Arbor, Michigan; with permission.)

photophobia can be a helpful distinguishing feature of anterior uveitis because it is not seen in other superficial causes of photophobia [1].

Posterior uveitis can cause “floaters” and visual changes but generally does not cause redness or significant pain. When the retina is involved, patients may complain of blind spots or flashing lights [15].

The diagnosis of uveitis is often confirmed by the presence of inflammatory cells and a proteinaceous flare in the anterior or posterior chambers of the eye on slit lamp examination. If inflammation is severe, leukocytes can settle in the anterior chamber and form a hypopyon, a white or yellowish accumulation of purulent material. This accumulation can sometimes be visible without the aid of magnification [5]. On slit lamp examination, deposits of white blood cells on the endothelium (keratic precipitates) are often visualized, which is a hallmark of iritis. Small-to-medium keratic precipitates are classified as nongranulomatous, whereas granulomatous (eg, sarcoid) keratic precipitates are large [16]. Infectious uveitis can be difficult to diagnose and usually requires specific findings on a detailed ophthalmologic examination, specific serology testing, or, after uveitis, does not respond to anti-inflammatory therapy [15]. The diagnostic evaluation in patients suspected to have a systemic condition requires further testing. Patients with pulmonary complaints should undergo chest radiography or CT or both to assess for possible sarcoidosis. Radiographic images of the sacroiliac joints and HLA-B27 typing are helpful when considering a spondyloarthropathy as a diagnosis. Colonoscopy should be done in patients with gastrointestinal symptoms or hemepositive stools to assess for inflammatory bowel disease [15]. These tests rarely need to be done in the emergency room or inpatient setting as long as an expedited outpatient work-up can be performed.

Uveitis is best managed in collaboration with an ophthalmologist. Initiation of therapy in a timely fashion is critical because of the severe sight-threatening complications associated with uveitis, including cataracts, glaucoma, and retinal detachment. Corticosteroids are the mainstay of

therapy in treating noninfectious causes [15]. Topical corticosteroids (eg, prednisolone acetate 1%) are used in anterior uveitis but are not helpful in posterior uveitis owing to poor penetration. This treatment may worsen this condition if there is a concern of an infectious etiology; therefore, it should only be prescribed after appropriate consultation with an ophthalmologist. Although cataracts can occur secondary to the inflammatory process, they are also a recognized complication of corticosteroids [15]. Mydriatic and cycloplegic agents are also often prescribed. Mydriatics (eg, phenylephrine HCl, hydroxyamphetamine HBr) are sympathomimetic agents used to prevent the formation of synechiae by pupillary dilation. A synechia is an adhesion where the iris adheres to either the cornea or lens. Although synechiae rarely cause visual problems, they can lead to secondary glaucoma. Parasympatholytic agents (eg, atropine sulfate, homatropine, cyclopentolate) produce both mydriasis and cycloplegia which block nerve impulses to the pupillary sphincter and ciliary muscle, reducing pain and photophobia [16]. Systemic corticosteroid therapy is usually reserved for bilateral disease that is refractory to local medication or for patients with significant ocular disability or retinitis. Other immunosuppressive medications may be used in steroid-dependent or refractory uveitis. In general, management of uncomplicated noninfectious uveitis can be done on an outpatient basis, but follow-up with an ophthalmologist should be arranged within 24 hours. Refractory cases or those secondary to an infectious cause often require admission and further diagnostic tests. Patients with suspected posterior uveitis who present with floaters or visual changes need urgent ophthalmology consultation [15].

Acute angle-closure glaucoma

AACG is a condition that develops when the peripheral tissue of the iris blocks the outflow of fluid from the anterior chamber, resulting in elevated intraocular pressure [1]. Mydriasis, such as in the low-light evening hours, can often worsen the condition as the accordion-like folds of the iris gather together into folds that cause obstruction. Mydriatic medications, systemic anticholinergics (eg, antihistamines or antipsychotics), and accommodation (ie, reading) can also cause pupillary block [7]. The patient with AACG will usually present with severe ocular pain, redness, a decrease in vision, and a pupil in mid-dilation [1]. Blurred vision, seeing halos around lights, and headache with nausea and vomiting may also be a part of the clinical presentation. Acute attacks may be self-limited and resolve spontaneously or may occur repeatedly. Patients who are elderly or far-sighted are at the highest risk for AACG because of enlargement of their lenses [7]. Because there are several other causes of a non-traumatic acute increase in intraocular pressure, such as glaucomatocyclitic crisis, inflammatory open-angle glaucoma, pigmentary glaucoma, and mechanical and postsurgical closure, the work-up should include a thorough history (family history, retinal

problems, recent laser treatment or surgery, medications), a slit lamp examination, and measurement of intraocular pressure [7].

On physical examination, AACG will usually present with a global injection pattern. There may be tearing but no other discharge. Corneal edema may make the cornea appear “steamy” or “hazy.” On slit lamp examination, there may be keratic precipitates, anterior chamber cells and flare, posterior synechiae, and a shallow anterior chamber. A fundoscopic examination that reveals optic nerve cupping indicates the need for urgent treatment. Perhaps the most important feature is that, on penlight examination, the pupil will be mid-dilated and nonreactive (Fig. 10A, B). If the pupil reacts, the diagnosis should be reconsidered [1]. Normal intraocular pressure is less than 21 mm Hg. Patients with glaucoma have an intraocular pressure greater than that, and those with an intraocular pressure greater than 30 mm Hg require prompt treatment. Most emergency departments are fitted with at least one instrument to allow measurement of intraocular pressure. The emergency physician should be familiar with the tools available in his or her workplace. The most common instruments used in the emergency department for measuring intraocular pressure are the tonopen and Schiøtz tonometer. Goldmann tonometry (applanation) may also be used. Other instruments include the MacKay-Marg tonometer. If infection is suspected, the clinician should be certain to use a sterile tip when using a contact tonometer. A simple and direct method to measure intraocular pressure is to gently press the globe through the eyelid while the patient is instructed to look down; the experienced practitioner may note differences in the “hardness” of one globe when compared with the other. Unfortunately, this method requires experience to gain accuracy, and most emergency physicians should use this only as a rough estimate [17].

Treatment for AACG mandates prompt and rapid transfer to an eye specialist. In the emergency department, 1 drop of 0.5% timolol can be administered, followed by another drop 5 minutes later. Topical steroids, such as 1%

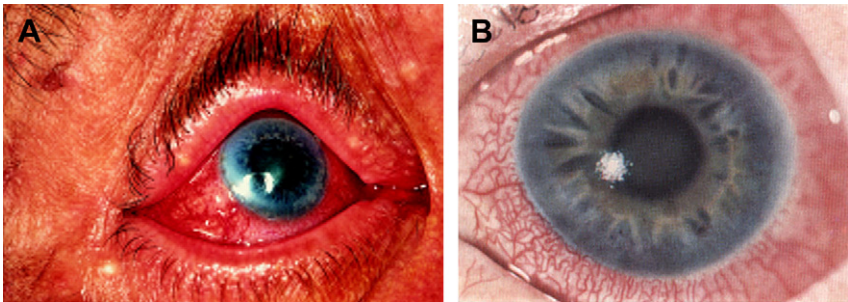


Fig. 10. (A, B) Acute angle-closure glaucoma. These close-ups reveal a global injection, a “hazy” appearance to the pupil, and a loss of iris structure. (Panel A is from Dayan M, Turner B, McGhee C. Lesson of the week: acute angle closure glaucoma masquerading as systemic illness. *BMJ* 1996;313:413–5; with permission; and Panel B is from Thiel R. *Atlas of diseases of the eye*, vol. I. New York: Elsevier; 1963. p. 255; with permission.)

prednisolone acetate, should be given every 15 to 30 minutes for four doses and then hourly [7]. Also, 1% topical apraclonidine or 0.15% or 0.2% topical bromonidine should be given for one dose [7]. Acetazolamide, a carbonic anhydrase inhibitor, can be given at a dose of 500 mg orally to help decrease the production of fluid. In cases of phakic pupillary block (in which there is a native, natural lens), pilocarpine, 1% to 2%, can be administered every 15 minutes for 2 minutes [7]. If vision has been compromised to detection of hand motion or worse, all topical medications not contraindicated, intravenous acetazolamide, and intravenous hyperosmotic fluid (such as mannitol) should be administered. Systemic symptoms such as pain and vomiting should be treated as appropriate with intravenous or oral medications. Definitive treatment includes peripheral iridotomy performed by either laser or incision. The fellow eye should receive a prophylactic iridotomy based on anatomy, because approximately one half of fellow eyes in patients with acute angle-closure will sustain acute attacks within 5 years [18]. The specialist may choose to delay definitive treatment until the inflammation has subsided.

Failure to recognize and treat AACG can result in excessive intraocular pressures that can damage the optic nerve and lead to visual loss. When evaluating a patient with migraine headache, it is prudent to document an eye examination and pupil reactivity because AACG can mimic migraine headache. One article highlights three cases in which the diagnosis of AACG was delayed or missed due to several factors that hindered appropriate and thorough evaluation. When patients are elderly, have disabilities such as dementia, deafness, or limited mobility, or have concurrent psychiatric or medical conditions, a thorough and directed history and physical (ie, using a slit lamp) may be problematic and challenging. In these cases, a high index of suspicion and a diligent work-up must be pursued when the presentation includes red eye, blurred vision, or headache [19].

Summary

The acutely red eye is a common complaint in the emergency department. Although most causes are benign and self-limiting, appropriate work-up and treatment can identify serious conditions and prevent significant morbidity such as blindness. As outlined herein, the emergency physician should obtain a relevant history and perform a thorough examination using the slit lamp and measurement of intraocular pressures when appropriate.

In general, patients who present with severe ocular pain, acute visual changes, corneal opacification, hypopyon, or blurred disk margins in the setting of a red eye warrant an aggressive search for serious causes and urgent ophthalmology referral. Topical analgesics should never be prescribed [5], and topical steroids should be initiated only after ophthalmology consultation. If the clinical presentation is concerning for scleritis and AACG, urgent consultation with the specialist for confirmation of diagnosis and initial management is recommended. Gonococcal conjunctivitis and posterior

Table 1
Common clinical findings in the acute red eye

Diagnoses	Pain hyperemia		Foreign body sensation	Discharge	Itching	Photophobia	Onset	Pupil	Cornea	Vision	Threat to vision	Timing of consultation
Episcleritis	No	Focal	No	Tearing	No	No	Rapid	Not affected	Clear	Not affected	No	Electively
Scleritis	Yes	Focal or diffuse	No	No	No	Yes	Progressive	Not affected	Occasional peripheral opacity	Not affected	Yes	Urgent
Uveitis	Yes	Diffuse, perilimbal	No	Watery, minimal	No	Yes	Sudden	Constricted, sluggish to light	May be hazy	Blurred	Yes	Within 24 hours
Allergic conjunctivitis	No	Diffuse, toward fornices	Yes	Watery to mucoid	Yes	No	Progressive	Not affected	Clear	Not affected	No	Electively
Viral conjunctivitis	No ^a	Diffuse, toward fornices	Yes	Watery and clear	Mild	No ^a	Sudden with rapid progression	Not affected	Clear	Not affected	No ^a	Electively
Bacterial conjunctivitis	No	Diffuse, toward fornices	Yes	Mucopurulent	Mild	No	Sudden	Not affected	Clear	Not affected	No	Usually elective
Subconjunctival hemorrhage	No	Focal or diffuse	No	No	No	No	Acute	Not affected	Clear	Not affected	No	Usually elective
Acute angle-closure glaucoma	Yes	Diffuse, perilimbal	No	Tearing	No	Yes	Sudden, usually in evening	Mid-dilated, nonreactive	Hazy	Blurred, halos around lights	Yes	Urgent

^a Can occur in patients with herpes zoster ophthalmicus.

uveitis associated with floaters also represent serious, sight-threatening conditions and similarly require urgent ophthalmology evaluation. Expedient follow-up with the specialist will help ensure that the patient has as little permanent damage to their vision as possible. With this in mind, one should remember that most causes of red eye in the emergency department are self-limiting and can be treated supportively. In general, patients with benign etiologies may receive follow-up from their primary care physician or the ophthalmologist electively to monitor for treatment effectiveness and for complications. The key clinical features and the urgency of consultation for the various diseases are outlined in [Table 1](#).

References

- [1] Roscoe M, Landis T. How to diagnose the acute red eye with confidence. *JAAPA* 2006;19(3):24–30.
- [2] Morrow GL, Abbott RL. Conjunctivitis. *Am Fam Physician* 1998;57(4):735–46.
- [3] Weber CM, Eichenbaum JW. Acute red eye: differentiating viral conjunctivitis from other, less common causes. *Postgrad Med* 1997;101(5):185–9.
- [4] Hara JH. The red eye: diagnosis and treatment. *Am Fam Physician* 1996;54(8):2423–30.
- [5] Leibowitz HM. The red eye. *N Engl J Med* 2000;343:345–51.
- [6] Wirbelauer C. Management of the red eye for the primary care physician. *Am J Med* 2006;119:302–6.
- [7] Kunitomo DY, Kanitkar KD, Makar MS, editors. *The Wills eye manual: office and emergency room diagnosis and treatment of eye disease*. 4th edition. Philadelphia: Lippincott Williams & Wilkins; 2004. p. 61, 71, 91, 94, 98, 155, 179–81.
- [8] Shaikh S, Ta CN. Evaluation and management of herpes zoster ophthalmicus. *Am Fam Physician* 2002;66(9):1723–30.
- [9] Prepared by the American Academy of Ophthalmology Cornea/External Disease Panel Cornea/External Disease Panel Members. American Academy of Ophthalmology. Conjunctivitis, preferred practice pattern. San Francisco (CA): American Academy of Ophthalmology; 2003. Available at: www.aao.org/ppp. Accessed August 11, 2007.
- [10] Roy FH. The red eye. *Ann Ophthalmol* 2006;38(1):35–8.
- [11] Walling AD. Tips from other journals: when is red eye not just conjunctivitis? *Am Fam Physician* 2002;66(12):2299–300.
- [12] Okhravi N, Odufuwa B, McCluskey P, et al. Scleritis. *Surv Ophthalmol* 2005;50(4):351–63.
- [13] Sowka JW, Gurwood AS, Kabat AG. Episcleritis. *Handbook of ocular disease management web site* 2000. Available at: <http://www.revoptom.com/HANDBOOK/sect2f.htm>. Accessed August 4, 2007.
- [14] Albini TA, Rao NA, Smith RE. The diagnosis and management of anterior scleritis. *Int Ophthalmol Clin* 2005;45(2):191–204.
- [15] Hajj-Ali RA, Lowder C, Mandell BF. Uveitis in the internist's office: are a patient's eye symptoms serious? *Cleve Clin J Med* 2005;72(4):329–39.
- [16] Nishimoto JY. Iritis. How to recognize and manage a potentially sight-threatening disease. *Postgrad Med* 1996;99(2):255–62.
- [17] Knoop KJ, Dennis WR. Ophthalmologic procedures. In: Roberts JR, Hedges JR, editors. *Clinical procedures in emergency medicine*. 4th edition. Philadelphia: Saunders; 2004. p. 1241–79.
- [18] American Academy of Ophthalmology. Primary angle closure, preferred practice pattern web site 2005. Available at: www.aao.org/ppp. Accessed August 5, 2007.
- [19] Gordon-Bennett P, Ung T, Stephenson C, et al. Misdiagnosis of angle closure glaucoma. *BMJ* 2006;333(7579):1157–8.